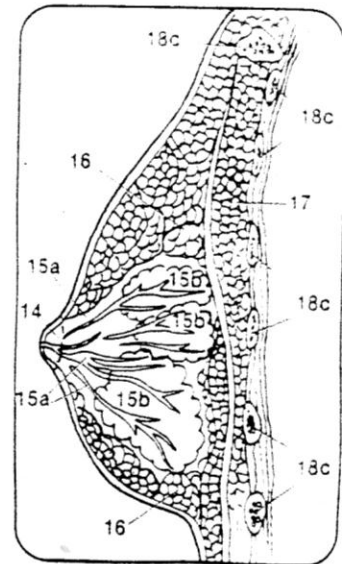
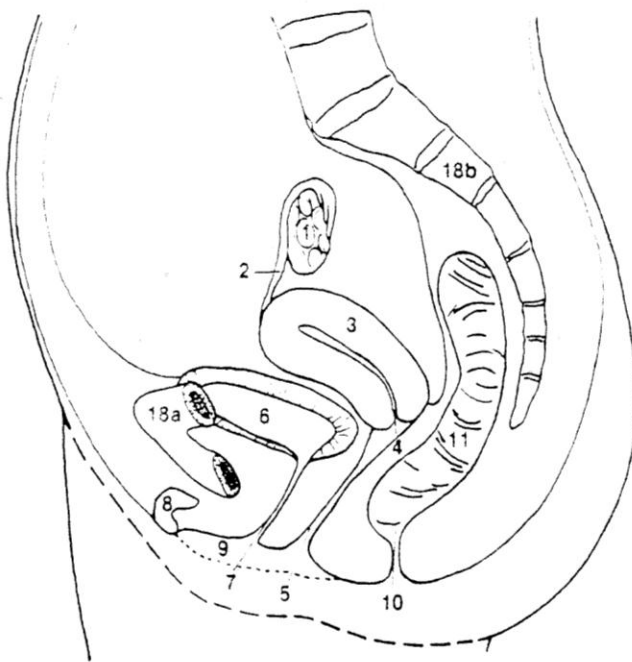


08 The Female Body Anatomy

The *vagina*, a tube-like potential space seven to ten centimeters long, receives the sperm from the male. The group of external organs surrounding the vagina are the *vulva*. The sperm must reach the *uterus* or womb, a hollow pear-shaped organ, through the *cervix*, the narrow end of the uterus. The uterus is lined with a mucous membrane and has small glands and many capillaries. At a certain time during the twenty-eight-day *menstrual cycle*, a *follicle* in the ovaries produces an *ovum* or egg, which is then carried into the *fallopian tubes* by ciliated cells in the tubes' lining. The cilia also assist the sperm as they swim up the tubes toward the egg. If a sperm enters the egg, a membrane that keeps out other sperm forms around the fertilized egg, now called a *zygote*. The zygote passes into the uterus in three to five days and becomes attached to its lining. The cells begin to multiply and develop into a fetus. During the nine months of gestation, the fetus is enclosed in the *placenta*, a membranous sac, and is nourished by and receives oxygen

from the mother's blood passing through the membrane via the *umbilical cord*. Wastes return through the placenta to the mother and are eliminated through her respiratory and excretory systems. As the fetus is developing, the mother's two *mammary glands* in her breasts begin to enlarge. These glands are composed of adipose as well as glandular tissue and secrete milk after the baby is born.



- | | |
|---|--------------|
| 1. OVARY | Light Green |
| 2. FALLOPIAN TUBE | Yellow-Green |
| 3. UTERUS | Green |
| 4. CERVIX | Blue |
| 5. VAGINA | Light Blue |
| 6. BLADDER | Pink |
| 7. URETHRA | Purple |
| 8. CLITORIS | Brown |
| 9. LABIA | Yellow |
| 10. ANUS | Orange |
| 11. RECTUM | Light Orange |
| 12. FETUS | Flesh |
| 13. UMBILICAL CORD | Light Purple |
| 14. NIPPLE | Red |
| 15. a. MAMMARY DUCTS and
b. LOBES <u>Mammary Lobes</u> | Turquoise |
| 16. FAT MAMMARY GLANDS | Gray |
| 17. PECTORALIS MAJOR (muscle) | Dark Blue |
| 18. a. PUBIS BONE; b. SPINE; and
c. RIBS | Light Brown |

